MPRI-JOMDR | INTERNATIONAL JOURNAL OF ORGANIC & MEDICINAL DEV. RESEARCH, VOL. 02 NO. 1 OCT-2023 ISSN: 1116 - 3089

EFFECTS OF RICIN TOXIN FROM CASTOR OIL SEED EXPOSURE ON THE LIVER OF ADULT WISTAR RATS

ADESANYA OLAYIOYE

Department of Crop and Environmental Protection, Ladoke Akintola University of Technology Ogbomoso.

Abstract

This study was designed to evaluate the effects of ricin toxin from castor oil seeds on Histology of experimental rats liver (Albino) for the benefits of reducing rodents pest population. The results shows a significant ($p<0.05$) highest liver weight in rats fed with control feed (8.83^{a}) when compared with rat fed with ricin toxin from castor oil seed (6.50^{b}), (5.25^{c}), (4.58^{c}), (4.50^{c}) and is clearly seen that increase in the dose and the function of a ricin toxin from castor oil seed affected the liver weight of tested rats.The result of all test liver showed histological features of lethal tissue damage in all the rat treated with ricin toxin examined. The control group showed normal tissue. The present findings clearly demonstrate that extract from castor oil seed is capable of inducing histopathological changes in the liver of the exposed rats. According to these results, it is suggested that plant with toxins like ricin exposure might cause hazardous effects, especially to living organisms.

Key words: Dichloromethane extract, Castor oil seed, Albino rat, Histology of liver.

EDITOR-IN-CHIEF

Prof. A.S. Hossein [Saskatchewan]

INTERNATIONAL JOURNAL – OMDR
VOL. 02 NO. 1 OCT-2023 ISSN: 1116 - 3089

INTRODUCTION

The liver is the largest solid organ, the largest gland and one of the most vital organs that functions as a centre for metabolism of nutrients and excretion of waste metabolites (Ozougwu, 2014). In addition, (Nunez, 2006) liver is responsible for metabolism and detoxification of the most of components that enter the body. Its primary function is to control the flow and safety of substances absorbed from the digestive system before distribution of these substances to the systemic circulatory system (Allen, 2002). A total loss of liver function could leads to death within minutes, demonstrating the liver‘s great importance (Ozougwu, 2014), in view of this, this study was undertaken to evaluate the effects of ricin toxin from castor oil seeds.

The liver weighs approximately 1500g and accounts for approximately 2.5% of adult body weight (Moore and Dalley, 2006). The surface of the liver is smooth and dome shaped, where it is related to the concavity of the inferior surface of the diaphragm. The liver lies mainly in the right upper quadrant of the abdomen where it is hidden and protected by the thoracic cage and diaphragm. The normal liver lies deep to the ribs 7 – 11 on the right side and crosses the midline towards the left nipple [5]. Venous blood from the entire gastrointestinal tract (containing nutrients from the intestines) is brought to the liver by the hepatic portal vein. Branches of this vein pass in between the lobules and terminate in the sinusoids. Oxygenated blood is supplied in the hepatic artery. The blood leaves the liver via a central vein in each lobule, which drains in the hepatic vein. Microscopic structure of the liver consists of the following:

Lobules: Hexagonally shaped functional units of the liver, made up of liver cells arranged in one-cell-thick plate-like layers that radiate from the central vein to the edge of the lobule.

EDITOR-IN-CHIEF
Prof. A.S. Hossein [Saskatchewan]

INTERNATIONAL JOURNAL – OMDR
VOL. 02 NO. 1 OCT-2023 ISSN: 1116 - 3089

Sinusoids: Small blood vessels between the radiating rows of hepatocytes. They receive oxygen-rich blood from the hepatic artery and nutrients from the intestines via the portal vein. Oxygen and nutrients diffuse through the capillary walls into the liver cells.

Portal area: Situated at the corner of each lobule, it is a complex composed of branches of the hepatic portal vein, hepatic artery, bile duct and nerve.

Bile ducts: Any of the ducts that convey bile from the liver. Bile is drained from the liver cells by many small ducts that unite to form the main bile duct of the liver, the hepatic duct. This joins the cystic duct, which leads from the gallbladder, to form the common bile duct, which drains into the duodenum.

Central vein: A blood vessel in the middle of each lobule which receives blood from the hepatic portal vein and hepatic artery via the sinusoids and drains the blood into the hepatic vein.

The liver is our greatest chemical factory, it builds complex molecules from simple substances absorbed from the digestive tract, it neutralises toxins, it manufactures bile which aids fat digestion and removes toxins through the bowels (Maton *et al*., 1993). But the ability of the liver to perform these functions is often compromised by numerous substances we are exposed to on a daily basis; these substances include certain medicinal agents which when taken in over doses and sometimes when introduced within therapeutic ranges injures the organ (Gagliano *et al*., 2007).

The liver regulates most chemical levels in the blood and excretes a product called bile, which helps carry away waste products from the liver. All the blood leaving the stomach and intestines passes through the liver. The liver processes this blood and breaks down the nutrients and drugs into forms that are easier to use for the rest of the body. The liver has many functions, Some of the more well-known functions primarily include the following: 1,Acting as a gatekeeper between the digestive system and the circulatory system. 2, Processing toxic substances before they enter general

EDITOR-IN-CHIEF
Prof. A.S. Hossein [Saskatchewan]

INTERNATIONAL JOURNAL – OMDR
VOL. 02 NO. 1 OCT-2023 ISSN: 1116 - 3089

circulation. 3, Storing and converting nutrients for future use. 4, Synthesizing most plasma proteins. 5, Secreting bile into small intestine to break down fats

The ricin is one of the most toxic materials known. Toxicity of ricin varies with caster plant species, route of administration, and purity of the toxin used. The median lethal dose of ricin has

been reported from 0.10 ng to 9.8 pglkg body weight through the intraperitoneal route. Orally, the ricin is less potent. Ingestion of three to five seeds may be lethal. The severity of seed toxicity depends upon mastication of seeds. Oral exposure results in nausea, vomiting, and diarrhea, hours after the exposures Ishiguro *et al.* (1992). Toxicity causes swollen lymph nodes with haemorrhage; spleen, liver, lungs, and heart are affected; body cavities contain clear fluid; hypothermia is observed; and death is accompanied by convulsions. Tissues with high turnover, eg, intestine, immune system are more severely affected than the other tissues.

MATERIALS AND METHODS

Site of the study: The experiment was carried out at the Toxicology Laboratory in the Department of Crop and Environmental Protection, Faculty of Agricultural Sciences, Ladoke Akintola University of Technology, Ogbomosho.

Animals and experimental design: The albino rats were obtained from the Virology Department, University College Hospital (U.C.H) Ibadan, Oyo State. They were kept in rat cages and fed with commercial rat feed (Growers mash) (Bova Jay Livestock Feeds, Nigeria Ltd). Thirty (30) experimental rats were divided into 3 replicates and each replicate had 5 cages. Each cage had 2 rats of both sexes. The age of the rats used for this experiment was 9 to10 weeks.

Preparation of the solvent crude extracts of the plants: The castor oil seed used for this experiment were obtained from the Botanical Garden Ladoke

EDITOR-IN-CHIEF
Prof. A.S. Hossein [Saskatchewan]

INTERNATIONAL JOURNAL – OMDR
VOL. 02 NO. 1 OCT-2023 ISSN: 1116 - 3089

Akintola University of Technology, Ogbomoso. The seeds were collected when ripe as the capsule, becomes dry, open and discharge the seeds. The 1000g of castor seed were crushed into coarse meal using pestle and mortar prior to extraction. The coarse meal of castor seed were then soak into 2000ml of Dichloromethane for 24 hour before it was later sieved with muslin cloth, the Dichloromethane extract gotten from castor oil seed was air-dry completely, 10ml, 20ml, 30ml and 40ml Dichloromethane extract gotten from castor oil seed, each was mixed thoroughly with 50 g of commercial rat feed, fifth one is Commercial rat feed only which was used as the control.

The treatments were as follows:

Treatment I: 10 ml Dichloromethane extract gotten from castor oil seed plus 50g of Commercial rat feed

Treatment II: 20 ml Dichloromethane extract gotten from castor oil seed plus 50g of Commercial rat feed

Treatment III: 30 ml Dichloromethane extract gotten from castor oil seed plus 50g of Commercial rat feed

Treatment IV: 40 ml Dichloromethane extract gotten from castor oil seed plus 50g of Commercial rat feed

Treatment V: Commercial rats feed only served as control

All the treatments were replicated three (3) times. The experiment lasted for 5 days

The rats were fed ad libitum (feeding without restriction) once daily with a baited powdered castor oil seed plus fried fish to treated rat and commercial feed to control rat, They were given fresh water once daily from a suspended water feeder.

Histopathological Studies: At the time of sacrifice, the liver were removed immediately after dissected and fixed or preserved in a 10% neutral

EDITOR-IN-CHIEF
Prof. A.S. Hossein [Saskatchewan]

buffered formalin for preservation before it was later sent to histopathological studies at the Histopathology Laboratory, University of Ilorin Teaching Hospital Ilorin, Kwara state. The result of Photomicrographs of the tissue taken were provided. This is done just to determine the mode of action of the plant materials used i.e. if it is the treatments applied or not, responsible for the tissue damage.

A histopathological examination was performed to monitor the morphological changes or the study of tissues at a microscopic level and its also termed microanatomy. Histopathology, on the other hand is the study of injured or affected tissues. Tissues examined first should be from animal that are clinically healthy. As a final portion of the exercises, examine tissues from infected animal and try to identify changes associated with infection.

Data Collection:

a. Fresh liver Weight organ of treated rat.

b. Fresh liver weight organ of untreated (control) rat.

Statistical Analysis

Data collected were analyzed using analysis of variance (ANOVA) and means were separated with Duncan Multiple Range Test (DMRT) at 5% level of probability using Statistical Analysis Software (SAS).

RESULT:

The histology of fresh liver weight, rats that were fed with control feed (normal feed) had highest liver weight and it is significantly difference from those treated with extract of castor oil seed. No significant difference was observed among the rat fed with 20ml, 30ml and 40ml extract of castor oil seed. This shows that the higher the concentration or dose, the more the damage (Fig 1).

INTERNATIONAL JOURNAL – OMDR
VOL. 02 NO. 1 OCT-2023 ISSN: 1116 - 3089

Sections of liver in plate 1 show the hepatocytesarranged as anastomosing cords and plates in radial orientation around terminal hepatic venules. Also shows a normal central vein and sinusoid. Features agree with normal liver histology. The section of liver in plate 2 shows a necrosis of the central vein (CV) as well as distorted sinusoid (S) and also shows ghost appearance of hepatocytes and foci of haemorrhages. Features are in keeping with ongoing hepatocellular death. Liver in plate 3 show a necrosis of the sinusoid (S), the plate of the hepatocytes (PP) and as well as the central vein (CV). The white blood cell (WB) also affected. Features are in keeping with severe hepatocellular necrosis. Section of the liver show severe enlargement of central vein (CV) as well as the sinusoid (S). The hepatocytes (H) are increase in number and there is presence of haemorrhage and foreign body. Features are in keeping with lysis of the cell in plate 4.

This section of the liver show a mild enlargement of the sinusoid(S), reduction of white blood cell and also, there is presence of haemorrhage.Features are in keeping with apoptosis of the cells in plate 5.

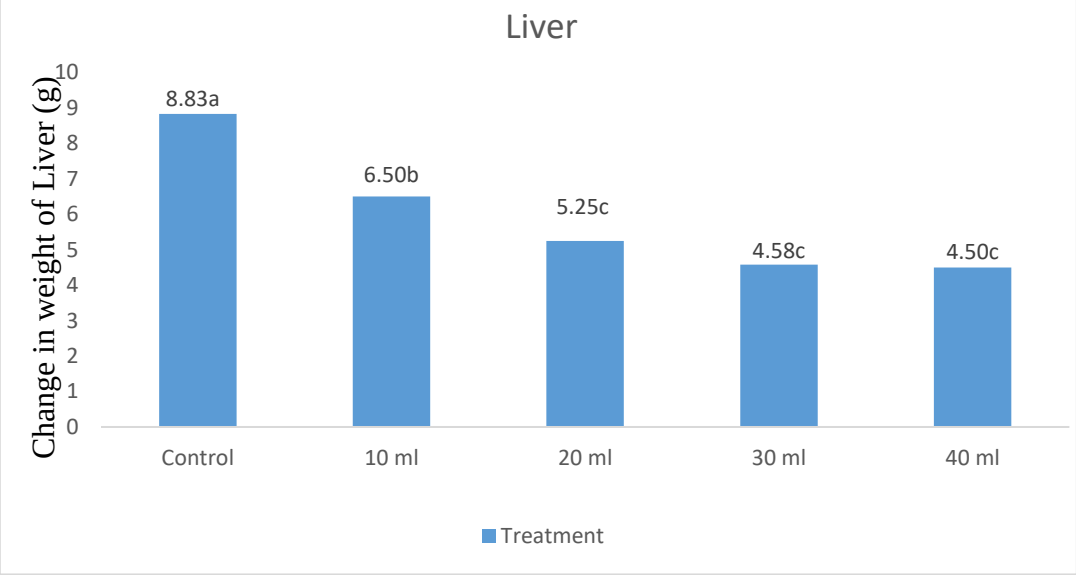

Figure 1. Effect of ricin toxin from castor oil seed on the liver weights of experimental rats

EDITOR-IN-CHIEF
Prof. A.S. Hossein [Saskatchewan]

INTERNATIONAL JOURNAL – OMDR
VOL. 02 NO. 1 OCT-2023 ISSN: 1116 - 3089

LEGEND

CV - Central Vein **H – Hepatocytes** **S - Sinusoid**

PH - Plate of hepatocytes **WBC - White blood cell**

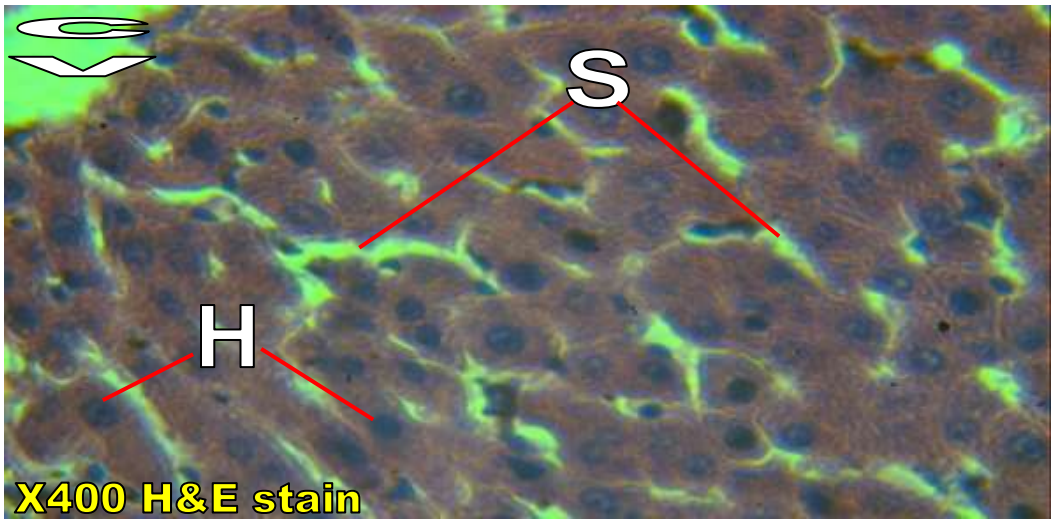

Plate 1. Histology of the normal liver (control group) of Albino (wistar rats). Mag X400 H & E Stain

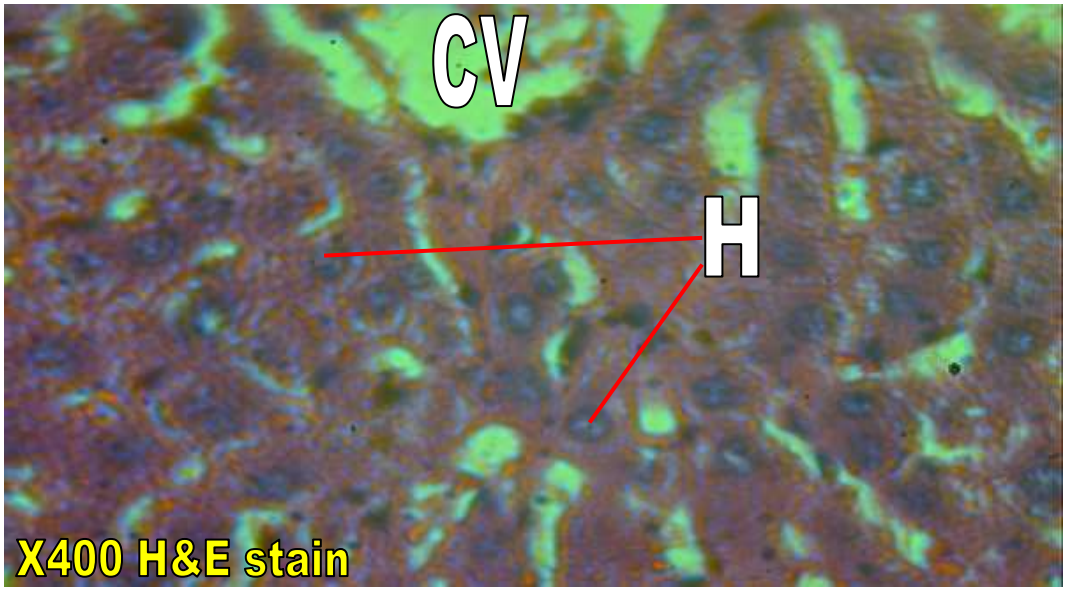

Plate 2. Histology of Albino liver treated with 10ml castor oil seed. Mag X400 H & E Stain.

EDITOR-IN-CHIEF
Prof. A.S. Hossein [Saskatchewan]

INTERNATIONAL JOURNAL – OMDR
VOL. 02 NO. 1 OCT-2023 ISSN: 1116 - 3089

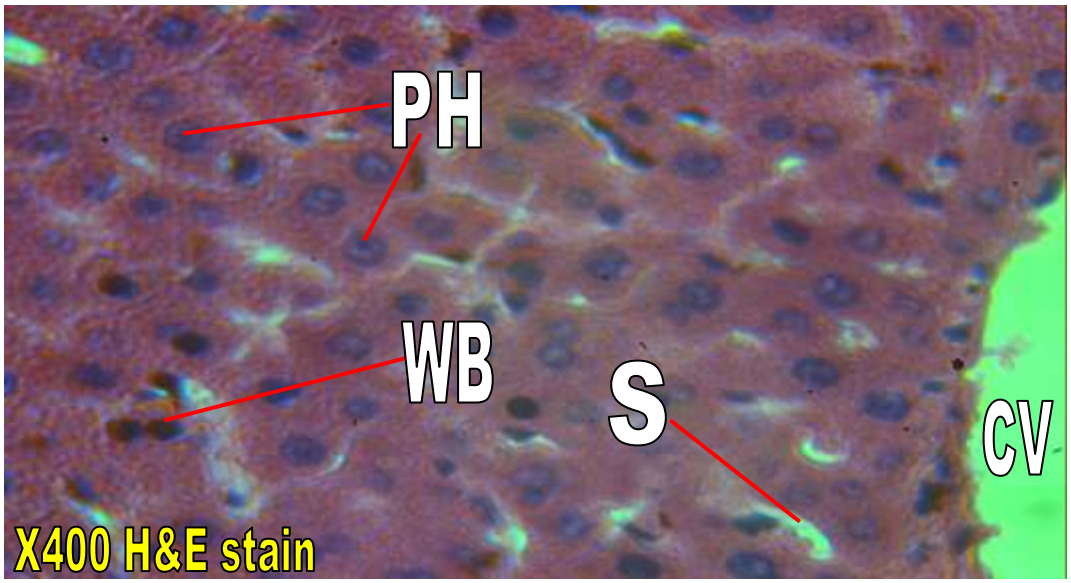

Plate 3: Histology of Albino liver treated with 20ml extract of extract of castor oil seed Mag X400 H & E Stain.

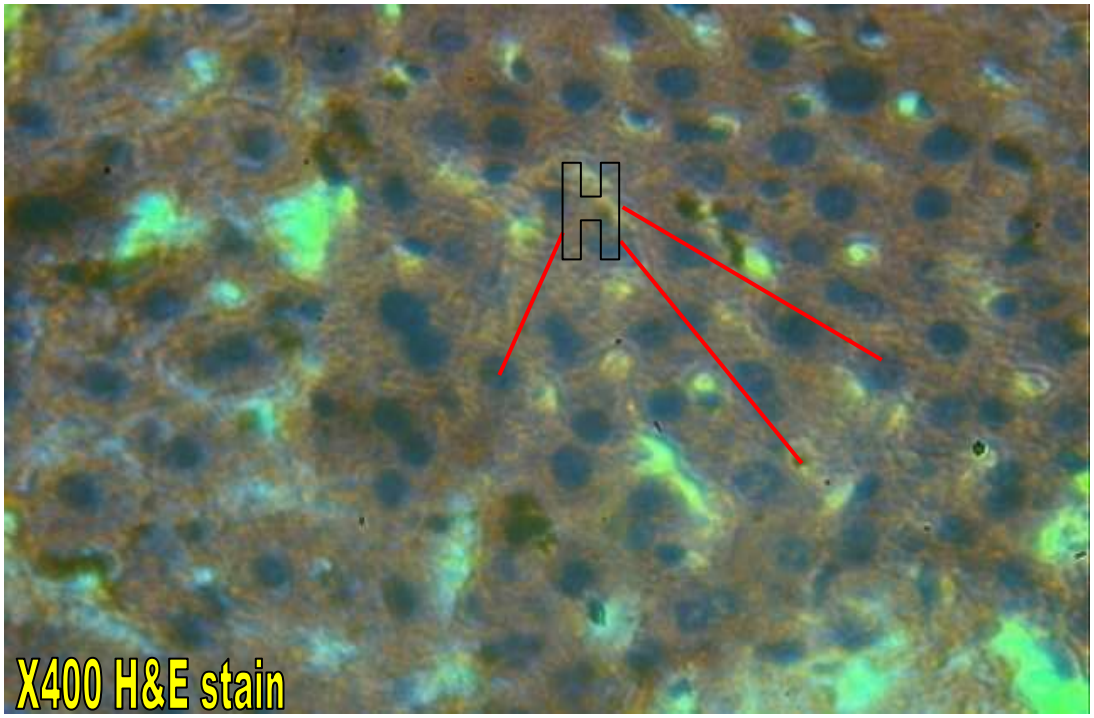

Plate 4: Histology of Albino liver treated with 30ml extract of castor oil seed.Mag X400 H & E Stain.

EDITOR-IN-CHIEF
Prof. A.S. Hossein [Saskatchewan]

INTERNATIONAL JOURNAL – OMDR
VOL. 02 NO. 1 OCT-2023 ISSN: 1116 - 3089

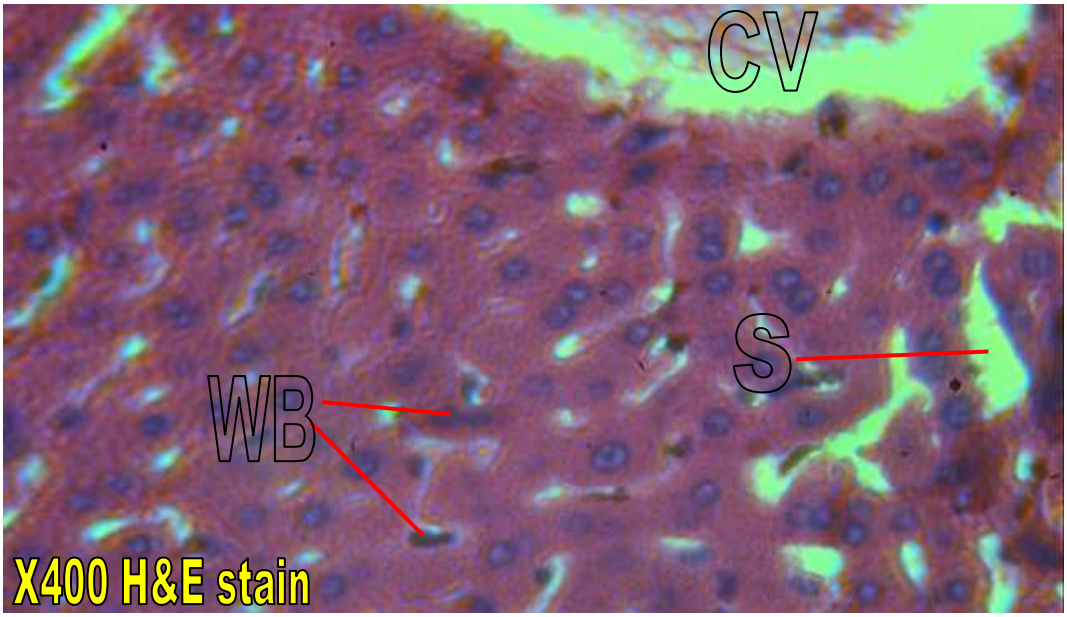

Plate 5: Histology of Albino liver treated with 40ml extract of castor oil seed; Mag X400 H & E Stain

DISCUSSION

The observation shows that the extract of castor oil seed has negative effect on liver weight. The negative effect depends on the concentrations applied that is why the rat fed with 20 ml, 30 ml and 40 ml higher concentration extract of castor oil seed has the least weight .

Pesticides have been shown to cause various histopathological changes in all the organs namely: kidney, liver, spleen, pancreas and stomach of experimental animals (Sulak O. *et al*., 2005).

The histology of liver is a vital organ present in vertebrates and some other animals. It has a wide range of functions, including detoxification, protein synthesis, and production of biochemicals necessary for digestion. The liver is necessary for survival; there is currently no way to compensate for the absence of liver function long term, although liver dialysis can be used short term.

EDITOR-IN-CHIEF
Prof. A.S. Hossein [Saskatchewan]

This organ plays a major role in metabolism and has a number of functions in the body, including glycogen storage, decomposition of red blood cells, plasma protein synthesis, hormone production, and detoxification (Cotran *et al*., 2005, Maton *et al*., 1993). The results of this study showed that there was normal histology of the liver with radially arranged sinusoids from the central vein and the hexagonal shape of the hepatocytes was maintained with viable hepatic cell (plate 1). where the tissue was intact with no sign of damage (i.e no reveal of any pathological alterations like necrosis, inflammation etc. the Dichloromethaneextract of castor oil seed is detrimental to the integrity of the liver tissues as evident in the necrotic nature of liver observed in Plate 2 & 3 above when compared with the control group (Plate. 1), There was distorted severe enlargement of central vein, sinusoids addition with presence of haemorrhage (see Plates 4 &5), Again there is loss of radial arrangement of sinusoids from the central vein of the liver and loss of hepatocytes when compared with the control (plate 1). Based on the histological observations in this study, we therefore inferred that the extract of castor oil seed caused damage to the liver tissues of Albino (wistar rats at any dose. Therefore, caution should be taken in its usage. The biochemical findings were also confirmed by histological observations. The changes mostly include hepatocellular necrosis or apoptosis, fatty accumulation, inflammatory cells infiltration and other histological manifestations which were also consistent with the findings of other authors (Brattin *et al.,* 1985; Sun *et al.,* 2001; Khan and Al-Zohairy 2011).

It has already been proven that castor seed contained ricin which is a type 2 ribosome inactivating protein (RIP) (Endo and Tsurugi 1987, Olnes and Phil. A. 2004, Stirpe, 2004). Ricin in castor oil seed is said to contain chain A and B. The chain B is neccessary for ricin to be able to elicit serious poisonous effects on cell [16]. Ricin with only chain A like the one present in barley has low toxic effect on the cell and is called type I ribosome inactivating protein

(Cornell University, 1999). This ricin causes the death of cells by inactivating ribosome which is necessary for protein synthesis (Wesche, 1999). Protein is known as building block of the body. It is useful in repair and replacement of worn-out organelles and cells, and also for general well being of tissues, inability of a cell to produce protein as seen in action of ricin on cell, might lead to cell death.

In summary, all test organs showed histological features of lethal tissue damage in all the rat liver treated with extract from castor oil seeds examined. The control group showed normal tissue.

The present findings clearly demonstrate that extract from castor oil seed is capable of inducing histopathological changes in the liver of the exposed rats. According to these results, it is suggested that plant with toxins like ricin exposure might cause hazardous effects, especially to living organisms.

REFERENCES

Allen SE. The liver: Anatomy, Physiology, Disease and Treatment. North Eastern University Press, USA. (2002).

Brattin WJ, Glende JEA, Recknagel RO, Pathological mechanisms in carbon tetrachloride hepatotoxicity. *J Free Radic Biol Med* **1**:27–38 (1985)

Cotran, R.S., V. Kumar, N. Fausto, F. Nelso, S.L. Robbins and A.K., Abbas, Robbins and Cotran pathologic basis of disease. St. Louis, MO: Elsevier Saunders. pp:878. ISBN0-7216-0187-1. (2005).

Cornell University. Ricin toxin from castor bean plant Ricinus communis.. From: http://ausci.Cornell.edu/plants/alphalist.html (1999)

Endo Y.,and Tsurugi K, "RNA N-glycosidase activity of ricin A-chain: mechanism of action of the toxic lectin ricin on eukaryotic ribosomes". *J Biol Chem* **262**: 8128 – 8130. (1987)

Gagliano, N., F. Grizzi and G. Annoni, Mechanism of aging and liver functions. Digest. *Dis. Sci*., **25**: 118-123 (2007).

EDITOR-IN-CHIEF
Prof. A.S. Hossein [Saskatchewan]

Ishiguro, M.; Tanabe, S.; Matori, Y. & Sakakibara, R. Biochemical studies on oral toxicity of ricin. IV. **A** fate of orally administered ricin in rats. *Journal of Pharmacobiodyn,* **15,** 147-56. (1992)

Khan, A.A, and Alzohairy, M, Hepatoprotective effects of camel milk againstCCl4-induced hepatotoxicity in Rats. *Asian J Biochem* **6(2):**171–180 (2011).

Maton, A., H. Jean, C.W . McLaughlin, M.Q. Warner, D. Lattart and J.D. Wright, Human Biology and Health. Eaglewood Cliffs, New Jersey, Prentice Hall, USA. (1993)

Moore KL, Dalley AF. Clinically Oriented Anatomy. 5th Edition Lippincott Williams and Wilkins. 1209 pp. (2006)

Nunez M, Hepatotoxicity of antiretrovirals: Incidence, mechanisms and management. *J Hepatol* **44**:132–139 (2006).

Olnes S.and Pihl A, "Different physio logical proprties of the two constituent peptide chains of ricin, a toxic protein inhibiting protein synthesis". Biochemistry **12**: 3121 – 26. (2004)

Ozougwu JC**,** Eyo JE. Hepatoprotective effects of *Allium cepa* extracts on paracetamol-induced liver damage in rat. *African Journal of Biotechnology* 2014, 13(26): 2679 -2688.

Ozougwu JC. Comparative hepatoprotective and antioxidant effects of *Allium cepa, Allium sativum* and *Zingiber officinale* methanolic extracts against paracetamol-induced liver damage in Rattus novergicus. Ph.D Research Thesis, Department Of Zoology and Environmental Biology, University of Nigeria, Nsukka. 222pp (2014)

Stirpe, F, Ribosome-inactivating proteins. *Toxicon* **44**, 371-383. (2004)

Sulak O, Altuntas I., Karahan N, Yildirim B, Akturk O, Yilmaz H. R. and Delibas N:*Pestic. Biochem. Phys*. **83**, 21-28. (2005)

Sun F, Hamagawa E, Tsutsui C et al, Evaluation of oxidative stress during apoptosis and necrosis caused by carbon tetrachloride in rat liver. *Biochim Biophys Acta* **1535:**186–191 (2001).

Wesche ,J, Dependance of Ricin toxicity on translocation of the toxin A-chain from the ER to the cytosol. *The Journal of Biological Chemistry* **274(48):** 3443-9. , (1999)