E-ISSN: 1116 - 3089 P-ISSN: 3026-9784
MPRI-JOMDR | INTERNATIONAL JOURNAL OF ORGANIC & MEDICINAL DEV. RESEARCH, VOL. 10 NO. 3 OCTOBER, 2025

ANTI-ANEMIC AND HISTOLOGY PROPERTIES OF *HIBISCUS SABDARIFFA* CALYX SUPPLEMENTED DIET IN PHENYLHYDRAZINE-INDUCED ANEMIA IN RATS

ADEROUNMU GANIYU IBRAHIM; ALIYU IBRAHIM; A. S. IDOKO; & BALKISU OYERONKE ABDULRAHMAN

Department of Biochemistry and Molecular Biology, Federal University Dutsin-Ma, P.M.B 5001, Katsina State, Nigeria.

Corresponding Author: i.aliyu_1959@fudutsima.edu.ng

DOI: https://doi.org/10.70382/mejomdr.v10i3.011

Abstract

Anemia is induced by oxidative stress and hemolysis, remains a major health concern. *Hibiscus sabdariffa* calyx is rich in anthocyanins and polyphenols with established antioxidant and hematopoietic potentials. This study investigated the anti-anemic and hepatoprotective effects of dietary *Hibiscus sabdariffa* calyx supplementation in phenylhydrazine-induced anemia in rats. Twenty-four adults male Wistar rats were divided into four groups (n = 4). Group I served as normal control; Group II received phenylhydrazine (PHZ; 12 mg/kg) to induce anemia; Groups III and IV were anemic rats fed 2% and 5% Hibicus sabdariffa calyx supplemented diets respectively, Treatments lasted six weeks post-induction. Hematological parameters were analyzed using an automated hematology analyzer, while liver and kidney tissues were examined histologically using hematoxylin and eosin staining. Penylhydrazine administration significantly ($p < 0.05$) reduced red blood cell count, hemoglobin, and packed cell volume compared to control. Supplementation with *Hibiscus sabdariffa* calyx significantly and dose-dependently improved these indices toward normal values. White blood cell and platelet counts were also normalized in treated

Keywords: *Hibiscus sabdariffa*, Anaemia, Phenylhydrazine, Hematological parameters, Hepatoprotection, Oxidative stress, Wistar rats

EDITOR-IN-CHIEF
Prof. A.S. Hossein [Saskatchewan]

groups. Histological examination revealed hepatocellular degeneration and necrosis in phenylhydrazine group, which were markedly ameliorated by *Hibiscus sabdariffa* supplementation, especially at 5% inclusion level, showing preserved hepatic architecture comparable to controls.

INTRODUCTION

Anemia is a clinical condition characterized by a reduction in hemoglobin level, hematocrit, or red blood cell count below the normal threshold for individuals of similar age, sex and physiological state under similar environmental conditions (WHO 2023). The World Health Organization defines anemia in children less than five years as a hemoglobin concentration below 11.0 g/dl while the thresholds of pregnant and non-pregnant women are 12.0 g/dl and 11.0 g/dl (WHO 2023).

In Nigeria alone, anemia is a critical public health concern, according to the World health organization Global Health Observatory (2023), more than 60% of children under five, 47% of non-pregnant women and 58% of pregnant women are anemic placing the country among those with the highest prevalence rates globally. Anemia contributes significantly to maternal and child morbidity and mortality in Nigeria where factors such as malaria, helminth infections, hemoglobinopathies and inadequate dietary iron intake play major roles (Eke *et al.,* 2023).

Phenylhydrazine is a strong redox active compound used in biomedical research to induce experimental hemolytic anemia. It uses its toxic effect by generating reactive oxygen species (ROS) which interact with hemoglobin leading to oxidative damage, methemoglobin formation, Heinz body accumulation and ultimately the disruption of red blood cell membrane (Wang *et al.,* 2023). The resulting oxidative stress shortens the lifespan of red blood cells from the normal 120 days to a significantly reduced period by mimicking hemolytic anemia in experimental models (Adeyemi *et al.,* 2024). The mechanism of Phenylhydrazine induced anemia involves hemoglobin oxidation, lipid peroxidation of the erythrocyte membrane and loss of membrane deformability which culminates in premature red blood cell destruction (Zhou *et al.,* 2023).

Hibiscus sabdariffa calyx Linn known as roselle or *zobo* in Nigeria is an annual herbaceous plant of the family *Malvaceae*. It is widely cultivated in tropical and subtropical regions, including Africa, Asia, and the Caribbean for its nutritional, medicinal and industrial significance (Singh and Gupta, 2025). Traditionally, it has been used in managing ailments such as hypertension, liver disorders, fever and anemia, its *calyx* are consumed as refreshing beverages rich in anthocyanins and phenolic compounds (Ekka, 2025). Phytochemical studies reveal that *Hibiscus sabdariffa calyx* is rich in bioactive compounds such as flavonoids, anthocyanins, organic acids and polysaccharides which contribute to

EDITOR-IN-CHIEF
Prof. A.S. Hossein [Saskatchewan]

its antioxidant, anti-inflammatory, antihypertensive, antidiabetic, antimicrobial and hepatoprotective activities (Cira-Chávez, 2025). Recent meta-analyses have confirmed its significant blood pressure lowering effects, positioning it as a promising adjunct in hypertension management (Obu, 2025).

Hibiscus sabdariffa calyx advances in green and enzymatic extraction methods now allow for sustainable recovery of its bioactive compounds, increasing its potential use in food, nutraceutical, and pharmaceutical industries (Cira-Chávez, 2025). Anthocyanins from roselle *calyx* particularly delphinidin-3-sambubioside and cyanidin-3-sambubioside have exhibit promising antitumor effects by suppressing angiogenesis enhancing immune cell recruitment synergizing with chemotherapy (Ezcurra-Hualde *et al.,* 2025). *Hibiscus sabdariffa calyx* (roselle) consumed as a traditional beverage in Nigeria which is rich in iron, vitamin C, anthocyanins and polyphenolic compounds which are known to enhance erythropoiesis, improve iron bioavailability and protect red blood cells from oxidative stress (Olayemi & Akinmoladun, 2021; El-Mahmoudy *et al.,* 2023). *Hibiscus sabdariffa calyx supplementation* significantly improves hematological parameters such as hemoglobin concentration and packed cell volume in Phenylhydrazine-induced anemia models (Akindahunsi *et al.,* 2024).

Regular consumption of *Hibiscus sabdariffa* calyx (usually teas or extracts from calyces) can reduce both systolic and diastolic BP, especially in pre-hypertensive or mildly hypertensive individual and Consumption of *Hibiscus sabdariffa calyx* is associated with lowering of oxidative stress markers, improved lipid profiles which contributes to reduced cardiovascular disease risk (Ellis *et al.,* 2022). The studies aimed to investigate anti-anaemic properties of *hibiscuss sabdariffa calyx* supplemented diets in Phenylhydrazine-induced anemia in rats.

Collection of plant material and identification

Dried *Hibiscus sabdariffa* calyx was bought from Dutsin-Ma market in Katsina State, the calyx was identified and authenticated by a botanist at the Plant Biology Department Herbarium of the Federal University Dutsin-Ma. *Hibiscus sabdariffa* calyx were thoroughly washed separately with water and subjected to drying for 72 hours in a well-ventilated area with regular stirring to achieve uniform drying. Following the drying process, the calyx was processed into fine powders utilising a laboratory grade blender.

Feed

Corn starch was prepared by soaking whole dried corn kernels for 48 hours, which was then ground to a smooth consistency and sieved using cheesecloth (0.02 mm-mesh). The residue was discarded, while the filtrate was allowed to stand overnight. The upper liquid

layer was filtered out, and the bottom starch layer was allowed to dry completely at room temperature. It was further ground into a smooth powder. The essential feed ingredients, such as soya bean meal (SBM), salt mix, cellulose, palm oil, methionine, and bone meal, were procured from a local vendor in katsina, Nigeria.

Feed Formulation

Standard rodent diet was prepared by approximately mixing corn starch, soybean meal (SBM), methionine, mineral mix, vitamin mix (pre-mix), cellulose, palm oil, salt and bone meal as in Table 1 (Ganiyu *et al.,* 2024).

Table 1: Components of the Standard diet

Feed component	Control diet (g/kg)
Corn starch	462
Soybean meal	330
Soybean oil	100
Cellulose	50
Vitamin premix	50
D-methionine	4
Salt	4
Total	1000

Diet Supplementation

Normal Diet was formulated from 100g of standard rat chow for the control and untreated group. The supplemented diet was f ormulated by mixing thoroughly 98g of standard rat chow with 2g of a mixture of *Hibiiscus sabdariffa calyx* powder in the group three 3. Subsequently mixing another formulated diet of 95g of standard rat chow with 5g mixture of *Hibiscus sabdariffa calyx powder in group 4.* The diet formulation was maximixe to achieve a balance in nutriotional properties with an attention on animal welfare.

Grouping of Experimental Animals

Following a seven days acclimatisation period, both male and female Wistar rats were randomly allocated into seven groups, ensuring comparable average weights across groups. The groups were organised as follows:

EDITOR-IN-CHIEF
Prof. A.S. Hossein [Saskatchewan]

Group 1: Normal control + standard rat chow
Group 2: Phenylhydrazine Induced animals + standard rat chow
Group 3: Phenylhydrazine Induced animals + 2% *Hibiscus sabdariffa calyx*
Group 4: Phenylhydrazine Induced animals + 5% *Hibiscus sabdariffa calyx*

Experimental Animals

Twenty-four (24) healthy Wistar rats (90g-120g) were obtained from the Animal house Department of Biochemistry and Molecular Biology Federal University Dutsin-Ma, Katsina state. They were housed in standard cages and acclimatized for seven (7) days under laboratory conditions at room temperature. The animals were maintained on the standard feed and water *ad libitum*.

Induction of Anemia

Phenylhydrazine was prepared in saline just before administration to avoid degradation. Phenylhydrazine at dose of 12mg/kg body weight dissolved in saline was injected intraperitoneally for 2 consecutive days according to the method of Olorunnisola et al. (2023) with slight modification.

Blood collection and organ

The study lasted for six (6) weeks after which the rats were weighed and sacrificed by exposing them to an over dose of chloroform soaked in cotton wool and sacrificed by cutting the jugular vein. Blood samples were collected in plain and EDTA tubes, then allowed to clot and the serum separated by centrifugation. This was followed by dissection using surgical scissors and forceps. The organs of interest liver and kidney were removed from the rats for histopathology.

Biochemical Assay

Randox Laboratories, Crumlin, UK, Commercial kits for liver enzymes (ALT, AST, ALP, TP, ALB, TB) - Randox Laboratories, Crumlin, UK, Commercial kits for kidney function (urea, creatinine, uric acid) - Randox Laboratories, Crumlin, UK, Reagents for total protein and albumin assessment - Roche Diagnostics, Basel, Switzerland, Sigma-Aldrich, St. Louis, MO, USA, Glutathione. Commercial assay kits for α1-Na, K-ATPase - MyBioSource, San Diego, CA, USA, Commercial assay kits for 5-α reductase - Hampton, NH, USA, Sodium hydroxide - Merck, Darmstadt, Germany, Quercetin (for flavonoid standard) - Sigma-Aldrich, St. Louis, MO, USA, Dragendorff's reagent - Sigma-Aldrich, St. Louis, MO, USA, Ferric chloride - Sigma-Aldrich, St. Louis, MO, USA, Tannic acid (for tannins standard) -Sigma-Aldrich, St. Louis, MO, USA.

EDITOR-IN-CHIEF
Prof. A.S. Hossein [Saskatchewan]

Haematological Analysis

An auto heamatological analyzer (XE-2100 by Sysmex Corporation) was used to determine the heamoglobin concentration (Hb), red blood cell count (RBC), total white blood cell count (WBC), lymphocytes, granulocytes, platelets, using the method of Dacie and Lewis (1991).

Statistical Analysis

Data obtained from the experiment were analyzed using the statistical package for social science (SPSS) software for windows version 21 (SPSS Inc., Chicago Illinois, USA) the results were reported as Mean ± SEM of the values and Duncan comparison was used to compare the mean values. $P<0.05$ was considered significant.

Red blood cells indices of Phenylhydrazine induced anemic rats fed *Hibiscus sabdariffa calyx* supplemented diet

Hemoglobin and hematocrit were significantly decreased ($p < 0.05$) in untreated group (group 2) compared to control. Group 3 (phenyl hydrazine-induced + 2% *Hibiscus sabdariffa calyx* supplemented diet) and group 4 (Phenyl hydrazine-induced + 5% *Hibiscus sabdariffa calyx* supplemented diet group) showed no significant differences from the control group 1, but a significanant increase shows compared to untreated group. Red blood cells counts were slightly but not significantly reduced in treated groups. MCV and MCHC remained statistically unchanged ($p > 0.05$).

Table 2: Red blood cells indices of phenylhydrazine induced anemia in rats fed *Hibiscus sabdariffa calyx* supplemented diet.

Groups	HGB(g/dl)	HCT (%)	MCV(fL)	MCHC(g/)	RBC(10^6/Ul)
Control	11.62±0.51^{b}	32.75±0.85^{b}	87.47±1.04^{a}	33.32±0.31^{a}	6.12±0.13^{a}
Untreated	8.87±0.25^{a}	24.25±0.94^{a}	83.05±2.01^{a}	32.47±0.70^{a}	5.37±0.17^{a}
2% H. S	12.12±0.91^{b}	35.50±0.47^{b}	84.77±1.96^{a}	33.93±0.37^{a}	6.07±0.34$^{a/b}$
5% H. S	11.27±0.48^{ab}	35.75±0.47^{b}	84.62±2.34^{a}	33.35±0.25^{a}	5.67±0.19$^{a/b}$

Group 1 (Control) + Normal diet
Group 2 (Untreated) phenylhydrazine-induced + Normal diets
Group 3 phenylhydrazine-induced + 2% *Hibiscus sabdariffa* calyx supplemented diet
Group 4 phenylhydrazine-induced + 5% *Hibiscus sabdariffa* calyx supplemented diet

EDITOR-IN-CHIEF
Prof. A.S. Hossein [Saskatchewan]

White blood cells indices of Phenylhydrazine induced anemia in rats fed *Hibiscus sabdariffa* calyx supplemented diet

It is observed that there are no significant changes in most of the white blood cells parameters, meanwhile, Platelets of the controls group tends to be higher, also no significant differences ($p > 0.05$) were observed in total WBC counts, lymphocytes among groups. It is observed that there are no significant changes in most of the white blood cells parameters, meanwhile, Platelets of the controls group tends to be higher. Phenyl hydrazine-induced + 5% *Hibiscus sabdariffa calyx* supplemented diet group, compared to the control group as presented in Table 8.

Table 3: White blood cells indices of Phenylhydrazine induced anemia in rats fed *Hibiscus sabdariffa calyx* supplemented diet

Groups	LYMPH%	GRAN%	PLT(10^3/Ul)	WBC(10^3/Ul)
Control	62.90±13.50^a	34.82±1.61^a	205.75±6.87^b	5.50±0.29^a
Untreated	67.67±1.37^a	31.00±2.74^b	173.45±3.35^a	4.62±0.49^a
2% H. S	63.55±1.80^a	35.52±3.11^a	168.77±0.73^a	5.20±0.23^a
5% H. S	61.82±2.56^a	33.35±3.04^a	164.35±5.63^a	4.00±0.66^a

Group 1 (Control) + Normal diet
Group 2 (Untreated) phenylhydrazine-induced + Normal diet
Group 3 phenylhydrazine-induced + 2% *Hibiscus sabdariffa* calyx supplemented diet
Group 4 phenylhydrazine-induced + 5% *Hibiscus sabdariffa* calyx supplemented diet

Concentration of Serum iron parameters of Phenylhydrazine induced anemia in rats fed *Hibiscus sabdariffa calyx* supplemented diet

Serum iron levels significantly increased ($P < 0.05$) across treatment groups, with the lowest value observed in Phenylhydrazine-induced + normal diet (group 2) compared to the control group and Phenylhydrazine-induced + 2% *Hibiscus sabdariffa calyx* group as presented in table 4

Table 4: Concentration of serum iron Phenylhydrazine induced anemia in rats fed *Hibiscus sabdariffa calyx* supplemented diet.

Groups	Concentration (MIU/ML)
Control	33.80±2.14^b
Untreated	13.57±0.84^a
2% *Hibiscus sabdariffa*	48.77±2.69^c
5% *Hibiscus sabdariffa*	80.62±0.63^d

EDITOR-IN-CHIEF
Prof. A.S. Hossein [Saskatchewan]

Group 1 (Control) + Normal diet
Group 2 (Untreated) phenylhydrazine-induced + Normal diet
Group 3 phenylhydrazine-induced + 2% *Hibiscus sabdariffa* calyx supplemented diet
Group 4 phenylhydrazine-induced + 5% *Hibiscus sabdariffa* calyx supplemented diet

Histophatology of liver in Phenylhydrazine induced anemia in rats fed *Hibiscus sabdariffa calyx* supplemented diet

Figure 1 shows the Histopathology of Liver of control and untreated groups of Phenylhydrazine induced wistar Rats fed *Hibiscus sabdariffa calyx* Supplemented Diet (H&E: X 400) revealed distinct variations in hepatocellular architecture. In the control group, the liver sections exhibited normal histoarchitecture characterized by well-arranged hepatocytes with intact cytoplasm and centrally located nuclei. No visible lesions or degenerative changes were observed. The untreated group shows a marked distortion of hyperplasia of inflammatory cells (LH). The hepatocytes appeared disorganized, indicating significant hepatic injury. In the 2% *Hibiscus sabdariffa calyx* group, the liver sections demonstrated hepatic necrosis (HN) compared with the untreated group. Hepatocytes showed healthier nuclei (HN) and reduced degenerative changes, though mild alterations were still present. In the 5% *Hibiscus sabdariffa calyx* group the liver histology appeared largely restored, with normal arrangement of hepatocytes, clear nuclei and minimal lesions as shown in Fig 1.

LIVER:

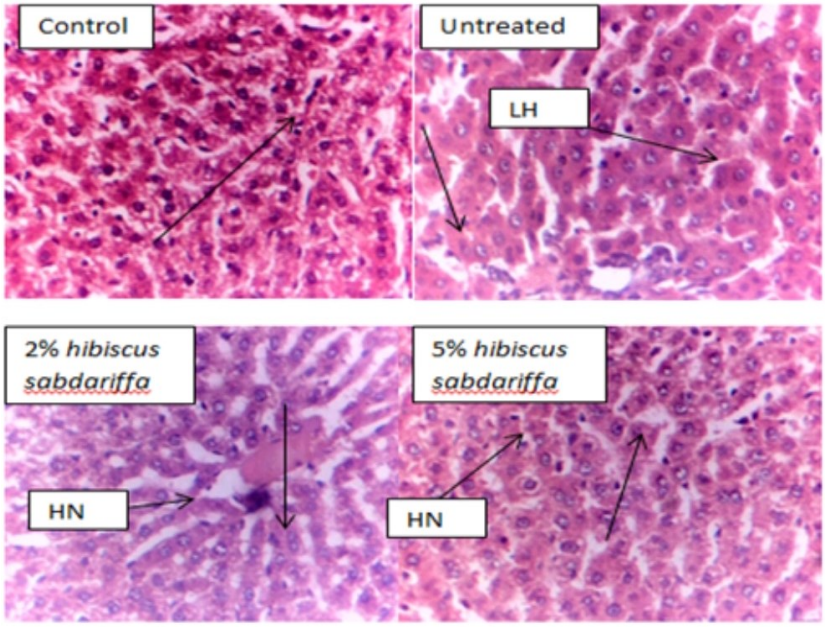

Figure 1: Histophatology of liver, control and untreated groups of phenylhydrazine induced Wistar Rats fed *Hibiscus sabdariffa calyx* Supplemented Diet (H&E: X 400) revealed distinct variations in hepatocellular architecture.

EDITOR-IN-CHIEF
Prof. A.S. Hossein [Saskatchewan]

Where:
LH: Hyperplasia of inflammatory cells
HN: Hepatic necrosis.

Histopathology of kidney in phenylhydrazine induced anemia in rats fed *Hibiscus sabdariffa calyx* supplemented diet.

The control group showed normal renal histoarchitecture with well-organized glomeruli and intact renal tubules. There was no evidence of vascular congestion, necrosis or degenerative changes. However, in the untreated group, there were observed distortion of kidney morphology with tubular necrosis (TN) and degenerative changes. This indicates renal injury and compromised renal function. In the 2% *Hibiscus sabdariffa calyx* group, sections showed some tubular adhension (TA), but the architecture appeared moderately preserved compared with the untreated group. Renal injury was less severe, suggesting a partial protective effect. In the 5% *Hibiscus sabdariffa calyx* group, Kidney sections showed largely preserved histoarchitecture, with healthy glomeruli, minimal lesions and reduced degenerative changes which closely resembled the control group.

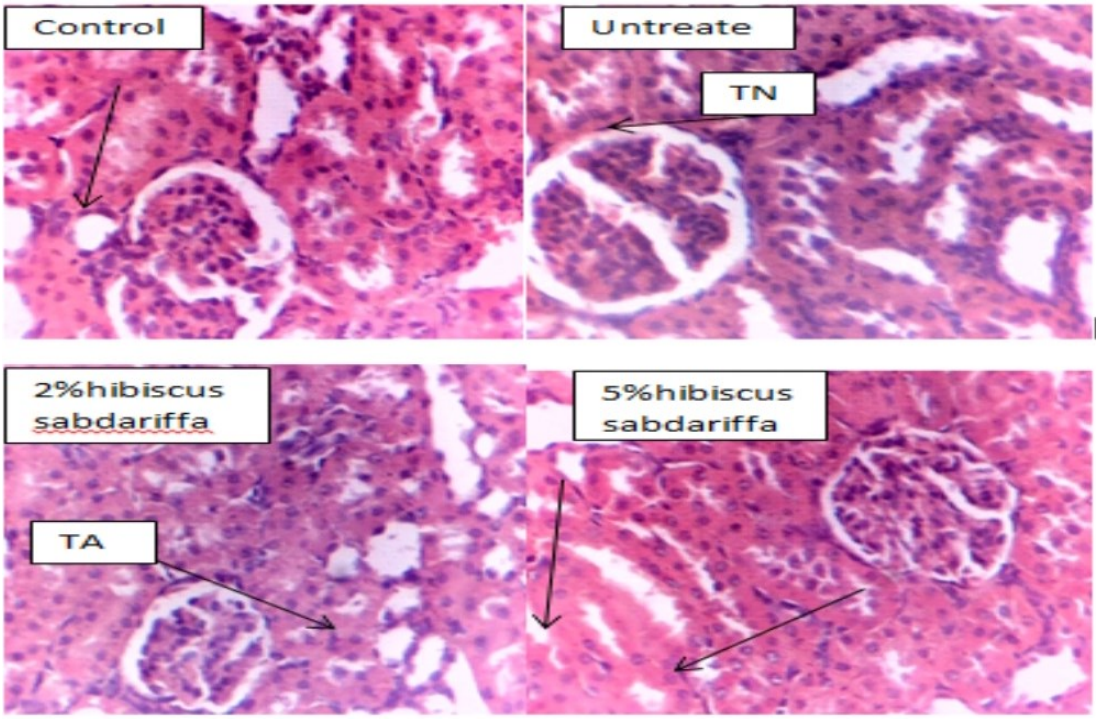

Figure 2 Histological examination of kidney tissue from the experimental groups showed control and untreated groups of Phenylhydrazine induced wistar Rats fed *Hibiscus sabdariffa calyx* Supplemented Diet (H&E: X 400).

EDITOR-IN-CHIEF
Prof. A.S. Hossein [Saskatchewan]

Where;
TN: Tubular necrosis
TA: Tubular adhension

Discussion

Phenylhydrazine induced anemia caused a significant reduction in red blood cell indices, while supplementation with *Hibiscus sabdariffa* calyx improved hematological parameters. The untreated anemic group recorded the lowest hemoglobin (HGB, HCT, MCV, MCHC and RBC count). These values show classical features of hemolytic anemia induced by phenylhydrazine, which promotes oxidative stress and accelerates erythrocyte destruction (Kumar *et al.,* 2020).

Rats fed with 2% *Hibiscus sabdariffa* calyx exhibited significant improvements in HGB, HCT and RBC count compared to the untreated group. The 5% supplemented group also showed increased HCT and stabilized HGB, though not as pronounced as the 2% group. These findings suggest that dietary supplementation with *Hibiscus sabdariffa* lessen hemolytic effects due to its antioxidant rich phytochemicals such as anthocyanins and flavonoids, which protect erythrocytes from oxidative lysis and promote erythropoiesis (Mahadevan *et al.,* 2022; Owoade *et al.,* 2023).

The improvement in hematological indices is consistent with previous studies reporting that *Hibiscus sabdariffa* enhances erythropoietin activity, restores hemoglobin synthesis and improves overall blood quality under oxidative stress conditions (Al-Mamun *et al.,* 2021). Moreover, the observed elevation of hematocrit (HCT) in both supplementation groups reflects improved oxygen carrying capacity which is crucial in reversing anemia related hypoxia (Chen *et al.,* 2021). Interestingly, the red blood cell (RBC) count was slightly higher in the control and 2% groups than in the 5% group, indicating that moderate supplementation may be more effective than higher doses. Excessive polyphenolic intake could interfere with nutrient absorption or exert pro-oxidant effects at high concentrations, thereby reducing hematological benefits (Ajiboye *et al.,* 2022).

The reduction in WBC count in the untreated group corroborates prior observations that phenylhydrazine induced oxidative stress impairs leukopoiesis and suppresses host defensee mechanisms (Okoli *et al.,* 2023). Supplementation with *Hibiscus sabdariffa* at 2% and 5% levels appeared to stabilize WBC counts, bringing them closer to the control values. This protective effect may be attributed to the high concentration of anthocyanins and polyphenolic compounds in *Hibiscus sabdariffa calyx* which are known to scavenge free radicals, modulate immune responses, and reduce cellular oxidative injury (Adeyemi *et al.,* 2023). Similar immunoprotective outcomes were reported by Mohammed *et al.* (2024), who demonstrated that *Hibiscus sabdariffa calyx* lessen leukocyte suppression in

chemically induced anemia models. Lymphocyte percentages did not significantly differ across treatment groups, indicating that *Hibiscus sabdariffa calyx* maintained immune homeostasis despite phenylhydrazine activity. Previous work has shown that *Hibiscus sabdariffa calyx* polyphenols support T-lymphocyte proliferation and cytokine regulation, which may explain the stable lymphocyte profile observed (El-Mahmoud *et al.,* 2024). Granulocyte percentages varied slightly but not significantly across groups. The minor changes of *Hibiscus sabdariffa calyx* supplemented diet did not markedly enhance granulopoiesis but rather contributed to maintaining normal granulocyte levels under oxidative stress conditions. Recent evidence indicates that hibiscus flavonoids can modulate neutrophil oxidative bursts and reduce inflammatory cytokine expression (Mansour *et al.,* 2024). Platelet counts in both untreated and supplemented groups compared to the control, while phenylhydrazine alone has been reported to induce thrombocytopenia through bone marrow suppression (Nwosu *et al.,* 2023), the further reduction in platelet count in *Hibiscus sabdariffa* supplemented diet in rats suggests a dose-dependent anti platelet effect. This aligns with earlier studies showing that *Hibiscus sabdariffa extract* inhibit platelet aggregation through downregulation of thromboxane A2 synthesis and cyclooxygenase pathway modulation (Salami *et al.,* 2024).

The reduction in serum iron concentration observed in the untreated Phenylhydrazine-induced rats compared to the control group confirms the oxidative and hemolytic effects of Phenylhydrazine which damages red blood cell membranes, leading to their premature destruction and subsequent iron loss (Wahid *et al.,* 2019). The supplemented diet of *Hibiscus sabdariffa calyx* significantly improved serum iron concentration in a dose-dependent manner, with the 5% supplementation group showing the highest iron levels. This enhancement can be attributed to the rich nutrient profile of *Hibiscus sabdariffa calyx* which contains iron and other polyphenols, anthocyanins act as potent antioxidants that reduce oxidative stress and protect erythrocytes from further hemolysis (Ali *et al.,* 2021). The improved iron status may also be linked to the stimulation of erythropoiesis by bioactive compounds present in *Hibiscus sabdariffa calyx*. *Hibiscus sabdariffa calyx* supplementation can restore hematological parameters altered by oxidative agents (Odigie *et al.,* 2003).

The histological findings from this study demonstrate that *Hibiscus sabdariffa calyx* exerts hepatoprotective effects against liver injury in a dose-dependent manner. The untreated group exhibited clear evidence of hyperplasia of inflammatory cells. These observations are consistent with earlier reports that liver injury is commonly associated with oxidative stress, inflammatory responses and hepatocellular necrosis (Weber *et al.,* 2019; Jaeschke *et al.,* 2021). Conversely, treatment with *Hibiscus sabdariffa calyx* restored hepatic morphology, with the 5% extract showing superior protective effects compared to 2%

Hibiscus sabdariffa calyx. This suggests that bioactive constituents of *Hibiscus sabdariffa calyx* including anthocyanins, flavonoids and phenolic acids which plays an important role in mitigating hepatocellular injury. These compounds are well-documented for their antioxidant, anti-inflammatory and free-radical scavenging activities (Ali *et al.,* 2019; Da-Costa-Rocha *et al.,* 2014). By reducing oxidative stress and stabilizing hepatocyte membranes, these phytochemicals prevent progressive hepatocellular damage and promote regeneration. The results align with previous studies that have reported the hepatoprotective properties of *Hibiscus sabdariffa calyx*. Similarly report shows an improvement in liver enzyme biomarkers and histological features following administration of *Hibiscus sabdariffa calyx* extract (Fakeye *et al.* 2018).

The control kidneys confirmed normal renal structure establishing the standard. The untreated group revealed clear evidence of renal damage manifested as tubular necrosis, consistent with nephrotoxicity or oxidative damage. Treatment with 2% *Hibiscus sabdariffa calyx* reduced the severity of injury but did not fully restore normal structure, indicating partial protection. 5% *Hibiscus sabdariffa calyx* was most effective, restoring renal architecture to near-normal, with intact glomeruli and reduced necrotic changes. These findings demonstrate that *Hibiscus sabdariffa calyx* confers dose dependent nephroprotection against renal injury. The untreated kidney sections revealed extensive tubular necrosis, features those are characteristic of oxidative stress induced nephrotoxicity and disruption of tubular epithelial integrity (Ortiz, 2021). Such damage can impair glomerular filtration and tubular reabsorption, ultimately compromising renal function. Administration of *Hibiscus sabdariffa calyx* resulted in notable improvements. The 2% treatment group exhibited reduced injury but still retained signs of necrosis, whereas the 5% group showed near normal histoarchitecture, suggesting stronger nephroprotective action at higher concentrations. The nephroprotective effect of *Hibiscus sabdariffa calyx* is likely attributed to its rich phytochemical composition, particularly flavonoids and polyphenols which possess antioxidant, anti-inflammatory and cytoprotective properties. These compounds have been reported to scavenge free radicals, reduce lipid peroxidation, stabilize cellular membranes and enhance renal tissue repair (Ali *et al.,* 2019; Da-Costa-Rocha *et al.,* 2014). The results of this study agree with previous reports that aqueous extracts of *Hibiscus sabdariffa calyx* protected renal tissues from chemically induced nephrotoxicity (Adeyemi *et al.* 2016). Similarly, Fakeye *et al.* (2018) reported improved renal biomarkers and histology in rats treated with *Hibiscus sabdariffa calyx* following toxic injury.

Conclusion

Hibiscus sabdariffa calyx supplementation in formulated diets contributed to have bioactive compound that Increase the level of Hemoglobin to 12.12±0.91 in 2% *Hibiscus*

sabdariffa calyx supplemented diet group and 11.27±0.48 in 5 *Hibiscus sabdariffa calyx* supplemented diet group respectively. *Hibiscus sabdariffa calyx* supplementation in formulated diets improves iron status, enhances antioxidant defenses and supports red blood cell recovery, making it beneficial for anemia management. Limited inclusion of (2%) offers a balanced nutritional profile with least renal stress, while higher inclusion (5%) maximizes mineral and antioxidant benefits but poses risks of electrolyte imbalance and mild renal strain, improve hepatic damage and preserves liver histoarchitecture. The high phytochemical and mineral contents of *Hibiscus sabdariffa calyx* support its therapeutic capacity, but dose levels are crucial for safety and efficacy.

Recommendation

- ✓ Based on the research findings, the study recommended that *Hibiscus sabdariffa calyx* should be incorporated into diets at moderate inclusion levels (around 2%) to achieve optimal health benefits, which dosage appears to provide sufficient mineral enrichment, improve antioxidant status, and enhance hematological parameters without causing significant electrolyte imbalance or renal stress.
- ✓ Anemia management at 5% inclusion may be considered for short-term interventions under monitored conditions due to its higher iron and antioxidant yield. However, long-term or high-dose use should be approached cautiously, particularly in individuals with pre-existing kidney or electrolyte disorders.
- ✓ Also, long term safety of higher inclusion levels, the bioavailability of its phytochemicals and minerals, and its efficacy across different age groups and health conditions, standardized processing and formulation methods should be adopted to ensure consistent nutritional outcomes.

REFERENCES

Adeyemi, A. O., Oladipo, O. H., & Akinyemi, T. R. (2024). Experimental models of anemia: Mechanistic insights and therapeutic evaluation. *Journal of Hematology Research, 15*(2), 112–124.

Adeyemi, D. O., Ukwenya, V. O., Obuotor, E. M., & Adewole, S. O. (2014). *Anti-hepatotoxic activities of Hibiscus sabdariffa L. in animal model of streptozotocin diabetes-induced liver damage*. **BMC Complementary and Alternative Medicine**, *14*, 277. https://doi.org/10.1186/1472-6882-14-277

Adeyemi, O. A., et al. (2023). Protective role of *Hibiscus sabdariffa* anthocyanins against oxidative stress-induced hematological alterations in rodents. *Journal of Ethnopharmacology, 311*, 116528. https://doi.org/10.1016/j.jep.2023.116528

Ajiboye, T. O., Akinmoladun, F. O., & Komolafe, T. R. (2022). Polyphenols in health and disease: Insights into hematological modulation. *Biomedicine & Pharmacotherapy, 152*, 113228. https://doi.org/10.1016/j.biopha.2022.113228

Akindahunsi, A.A., Adedapo, A.A., & Oyedele, O.R. (2024). Hematopoietic and antioxidant effects of *Hibiscus sabdariffa calyx* aqueous extract in Phenylhydrazine-induced anemic rats. *Advances in Science and Botany*, 2(3), 45–54.

Ali, B. H., Al Wabel, N., & Blunden, G. (2021). Phytochemical, pharmacological and toxicological aspects of *Hibiscus sabdariffa calyx* L.: A review. *Phytotherapy Research*, 35(4), 1774–1791. https://doi.org/10.1002/ptr.6891

Ali, B. H., Al-Wabel, N. A., & Blunden, G. (2019). Phytochemical, pharmacological and toxicological aspects of *Hibiscus sabdariffa calyx* L.: A review. Phytotherapy Research, 29(1), 1–13. https://doi.org/10.1002/ptr.5210

Al-Mamun, M., Sayeed, A., & Rahman, M. (2021). Dietary antioxidants in hematological modulation: Evidence from animal models. *Antioxidants, 10*(6), 921. https://doi.org/10.3390/antiox10060921

Chen, J., Li, H., & Xu, X. (2021). Oxidative stress in anemia: Pathophysiology and nutritional intervention. *Nutrients, 13*(9), 3030. https://doi.org/10.3390/nu13093030

Cira-Chávez, L. A. (2025). Green extraction of bioactive compounds from *Hibiscus sabdariffa calyx* calyx: A sustainable technological advancement. *Journal of Food Bioactives, 19*, 45–58. https://doi.org/10.1016/j.jfba.2025.100454

Da-Costa-Rocha, I., Bonnlaender, B., Sievers, H., Pischel, I., & Heinrich, M. (2014). *Hibiscus sabdariffa calyx* L. – A phytochemical and pharmacological review. Food Chemistry, 165, 424–443. https://doi.org/10.1016/j.foodchem.2014.05.002

Eke, R. A., Okafor, I. M., & Nwaokoro, J. C. (2023). Prevalence and determinants of anemia among pregnant women in Nigeria: A systematic review. *BMC Pregnancy and Childbirth, 23*(1), 445. https://doi.org/10.1186/s12884-023-05921-3

Ekka, R. (2025). Phytochemical impact of *Hibiscus sabdariffa calyx Linn.* on inflammation: A comprehensive review. *Journal of Functional Foods Advances, 7*, 112–124. https://doi.org/10.1016/j.jffa.2025.100087

Ellis L. R., Zulfiqar S., Holmes M., Marshall L., Dye L., Boesch C. *A systematic review and meta-analysis of the effects of Hibiscus sabdariffa on blood pressure and cardiometabolic markers.* Nutrition Reviews. 2022;80(6):1723-1737.

El-Mahmoudy, A., *et al.* (2023). Protective effects of *Hibiscus sabdariffa calyx calyx* extract against oxidative stress and anemia in rats. *Scientific African*, 20, e01437. https://doi.org/10.1016/j.sciaf.2023.e01437

Ezcurra-Hualde, M., López-Fernández, A., García-Martínez, E., & Ramírez-Sánchez, M. (2025). Intratumoral administration of *Hibiscus sabdariffa calyx* -derived anthocyanins enhances chemotherapy efficacy and promotes antitumor immune responses. *Frontiers in Immunology, 16*, 1549890. https://doi.org/10.3389/fimmu.2025.1549890

Fakeye, T. O., Itiola, O. A., & Odelola, H. A. (2018). Hepatoprotective effect of aqueous extract of *Hibiscus sabdariffa calyx* in rats. Journal of Ethnopharmacology, 222, 54–62. https://doi.org/10.1016/j.jep.2018.04.011

Jaeschke, H., Ramachandran, A., & Chao, X. (2021). Emerging and established modes of cell death in liver diseases. Journal of Hepatology, 75(5), 1136–1150. https://doi.org/10.1016/j.jhep.2021.07.019

Kumar, A., Singh, S., & Verma, A. (2020). Phenylhydrazine-induced anemia in rodents: Mechanisms and protective strategies. *Journal of Applied Hematology, 11*(4), 162–170. https://doi.org/10.4103/joah.joah_47_20

Mahadevan, N., Shivali, S., & Kamboj, P. (2022). *Hibiscus sabdariffa* Linn.: Phytochemistry, pharmacology and clinical applications. *Frontiers in Pharmacology, 13*, 935416. https://doi.org/10.3389/fphar.2022.935416

Mansour, M. H., et al. (2024). Polyphenolic extracts of *Hibiscus sabdariffa* modulate neutrophil-mediated inflammation via antioxidant pathways. *Frontiers in Pharmacology, 15*, 1456721. https://doi.org/10.3389/fphar.2024.1456721

Mohammed, A. S., et al. (2024). Hematoprotective effects of *Hibiscus sabdariffa* in phenylhydrazine-induced anemia models. *BMC Complementary Medicine and Therapies, 24*, 182. https://doi.org/10.1186/s12906-024-03821-9

Nwosu, J. N., et al. (2023). Oxidative and hematological consequences of phenylhydrazine-induced anemia in rats. *Toxicology Reports, 10*, 185–194. https://doi.org/10.1016/j.toxrep.2023.01.015

Obu, R. N. (2025). Systematic review and meta-analysis of *Hibiscus sabdariffa calyx* in hypertension management. *Journal of Complementary and Alternative Medical Research, 26*(1), 37–58. https://doi.org/10.9734/jocamr/2025/v26i1613

Odigie, I. P., Ettarh, R. R., & Adigun, S. A. (2003). Chronic administration of aqueous extract of *Hibiscus sabdariffa calyx* attenuates hypertension and reverses cardiac hypertrophy in 2K-1C hypertensive rats. *Journal of Ethnopharmacology*, 86(2–3), 181–185. https://doi.org/10.1016/S0378-8741(03)00078-2

Olayemi, F.O., & Akinmoladun, F.O. (2021). Antioxidant and mineral composition of *Hibiscus sabdariffa calyx calyx* and its potential in anemia management. *Nigerian Journal of Nutritional Sciences*, 42(2), 65–74.

Olorunnisola, O. S., Ogunlade, B., Akinmoladun, F. O., *et al.* (2023). Hematopoietic and antioxidant potential of *Moringa oleifera* leaf extract in Phenylhydrazine-induced anemic rats. *Scientific African*, 19, e01423.

Owoade, A. O., Adeyemi, T. A., Ortiz, A. (2021). Key unsolved issues in kidney replacement therapy. *Journal of Internal Medicine*. 2021. (discussion of tubular dysfunction and clinical implications).

Salami, A. T., et al. (2024). Anti-thrombotic potential of *Hibiscus sabdariffa* calyx extract: Modulation of platelet aggregation and coagulation markers. *Phytomedicine Plus, 5*(2), 100317. https://doi.org/10.1016/j.phyplu.2024.100317

Singh, P., & Gupta, R. (2025). *Hibiscus sabdariffa calyx* : A comprehensive review of its phytochemistry, traditional uses, and therapeutic potentials. *International Journal of Herbal Medicine, 13*(4), 1–8. https://www.florajournal.com/archives/2025/vol13issue4/PartA/13-1-8-159.pdf

Wahid, F., Khan, N., & Saeed, M. (2019). Mechanism of Phenylhydrazine-induced anemia in experimental animals. *Brazilian Archives of Biology and Technology*, 62, e19180514. https://doi.org/10.1590/1678-4324-2019180514

Wang, Y., Li, H., & Zhang, J. (2023). Oxidative mechanisms of Phenylhydrazine-induced hemolysis: Implications for red cell biology. *Free Radical Biology and Medicine, 201*, 45–55. https://doi.org/10.1016/j.freeradbiomed.2023.07.014

Weber, L. W. D., Boll, M., & Stampfl, A. (2019). Hepatotoxicity and mechanism of action of haloalkanes: Carbon tetrachloride as a toxicological model. Critical Reviews in Toxicology, 33(2), 105–136. https://doi.org/10.1080/713611034

World Health Organization (WHO). (2023). Global health estimates: Anemia prevalence and trends. Geneva: World Health Organization. https://www.who.int/data/gho

Zhou, M., Chen, L., & Guo, X. (2023). Redox imbalance and membrane damage in Phenylhydrazine-induced anemia. *Toxicology Reports, 10*, 134–142. https://doi.org/10.1016/j.toxrep.2023.01.015

EDITOR-IN-CHIEF
Prof. A.S. Hossein [Saskatchewan]